

Report

Hereditary Sensory Neuropathy Type I: Haplotype Analysis Shows Founders in Southern England and Europe

G. A. Nicholson,¹ J. L. Dawkins,¹ I. P. Blair,¹ M. Auer-Grumbach,² S. B. Brahmabhatt,¹ and D. J. Hulme¹

¹ANZAC Research Institute, University of Sydney, Sydney; and ²Department of Neurology, Karl-Franzens University, Graz, Austria

Hereditary sensory neuropathy type I (HSN1) is the most common dominantly inherited degenerative disorder of sensory neurons. The gene mutation was mapped to chromosome 9 in a large Australian family, descended from an ancestor from southern England who was a convict. Dawkins et al. recently reported gene mutations in the *SPTLC1* gene, in this and other families. The first description of hereditary sensory neuropathy, by Hicks, was in a family from London and Exeter. To determine if the families in the present study that have *SPTLC1* mutations are related to English families with HSN1 and, possibly, to the family studied by Hicks, we performed haplotype analysis of four Australian families of English extraction, four English families, and one Austrian family. Three Australian families of English extraction and three English families (two of whom have been described elsewhere) had the 399T→G *SPTLC1* mutation, the same chromosome 9 haplotype, and the same phenotype. The Australian and English families may therefore have a common founder who, on the basis of historical information, has been determined to have lived in southern England prior to 1800. The sensorimotor neuropathy phenotype caused by the 399T→G *SPTLC1* mutation is the same as that reported by Campbell and Hoffman and, possibly, the same as that originally described by Hicks.

Hereditary sensory neuropathy type I (HSN1 [MIM 162400]) is a dominantly inherited sensorimotor axonal neuropathy accompanied by variable sensorineural deafness (for review, see Thomas 1993). The presence of severe sensory loss leads to painless injuries, chronic skin ulcers, and distal amputations, distinguishing the disorder from other dominantly inherited sensorimotor neuropathies—such as Charcot-Marie-Tooth (CMT) type 2 syndromes—although, occasionally, patients with CMT type 1 or 2 develop skin ulcers.

In past literature, there have been many terms for this disease, including “trophoneurosis,” “lumbosacral syringomyelia,” and “ulcero-mutilating acropathy.” This literature has been reviewed by Dyck et al. (1993), who classified the disease as hereditary sensory and autonomic neuropathy (Dyck et al. 1993); however, frank

autonomic symptoms and signs are rare in the families in the present study, but motor signs are present in all but early cases.

An English family with a phenotype similar to that of the large Australian family described elsewhere and herein (family 1 in this report) was reported, by Hicks (1922), as having hereditary perforating ulcer of the foot. The same family was later reported, by Denny-Brown (1951), as having hereditary sensory radicular neuropathy. One year later, the same family was reported as having peroneal muscular atrophy with severe sensory changes (England and Denny-Brown 1952), a description that recognized motor involvement. These reports underlie the overlap between HSN1 and the other dominantly inherited hereditary sensorimotor neuropathies (e.g., CMT neuropathies). This problem was recognized by Dyck et al. (1993), who felt that an improved classification would depend on identification of the gene abnormality.

Foot ulcers are common in an axonal form of CMT type 2 neuropathy linked to chromosome 3 (Kwon et al. 1995; De Jonghe et al. 1997). This form of CMT

Received May 24, 2001; accepted for publication July 9, 2001; electronically published July 27, 2001.

Address for correspondence and reprints: Dr. G. A. Nicholson, University of Sydney, Clinical Sciences Building, Concord Hospital, Concord, NSW 2139, Australia. E-mail: molmed@med.usyd.edu.au

© 2001 by The American Society of Human Genetics. All rights reserved. 0002-9297/2001/6903-0019\$02.00

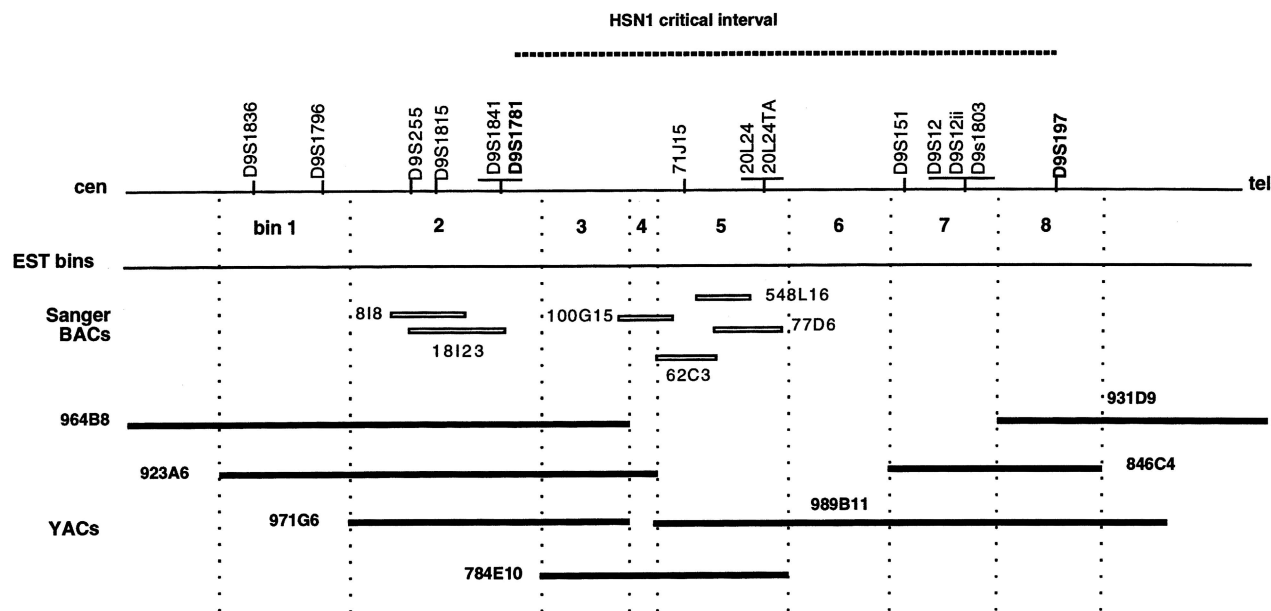


Figure 1 Physical map of interval between D9S1836 and D9S197, showing relative positions of markers used to define HSN1 haplotype. The markers shown in boldface define the boundaries of the HSN1 critical interval (D9S1781–D9S197) described elsewhere. The three new microsatellite markers (71J15, 20L24, and 20L24TA) all map to bin 5. *SPTLC1* maps to bin 3.

could also be classified as hereditary sensory neuropathy (Vance et al. 1996).

We have used the term “HSN1” to describe this form of dominantly inherited sensorimotor axonal neuropathy with variable sensorineural deafness (Thomas 1993). We previously mapped the *HSN1* locus to chromosome 9 (Nicholson et al. 1996), in the large Australian family (family 1) with clinical features similar to those in the London/Exeter family studied by Hicks (1922) and Denny-Brown (1951), and recently found mutations in the *SPTLC1* gene (Dawkins et al. 2001), both in family 1 and in 10 other families with HSN1. The Australian family was originally described as having familial lumbosacral syringomyelia (Jackson 1949), and, later, the same family was reported as having hereditary sensory radicular neuropathy (Wallace 1969, 1970). HSN1 is genetically heterogeneous, with at least three loci: chromosome 9 (Nicholson et al. 1996; Bejaoui et al. 1999); a chromosome 3 locus (Kwon et al. 1995), for a form of CMT type 2 suggested to be similar to HSN1 (Vance et al. 1996); and at least one other locus, for families without linkage to either of these two loci (Auer-Grumbach et al. 2000).

To determine whether the Australian and English families have a common founder and whether the phenotype described by us is likely to be the same as that originally described by Hicks (1922), we generated additional microsatellite markers and constructed a disease haplotype for each family. Multigenerational families with a di-

agnosis of HSN1 and with mutations in *SPTLC1* were selected. The clinical diagnosis of HSN1 was based on (1) a history of either chronic skin ulcers or painless injuries, (2) gross sensory loss in all modalities, and (3) electrophysiological evidence of a chronic axonal neuropathy. Severe, brief shooting pains were characteristic of HSN1 but were not a selection criterion. Sensorineural deafness was present in some members of some families. Australian families 1, 2, 4, and 6 have been described elsewhere (but identified as families 1, 3, 2, and 4, respectively; Nicholson et al. 1996). One of the English families (family 24) has previously been characterized, by Campbell and Hoffman (Campbell and Hoffman 1964), as family X.

Fourteen microsatellite markers on chromosome 9 were analyzed in each of the nine families with HSN1, as well as in the control individuals. These markers included three new polymorphic microsatellites (71J15, 20L24, and 20L24TA) that we isolated from cosmids within the HSN1 critical region. All 14 microsatellite markers were localized to our 8-Mb yeast-artificial-chromosome (YAC)-based physical map of the HSN1 critical interval (Blair et al. 1998). Figure 1 shows the locations of the 3 new markers and of 13 markers described elsewhere, in relation to the HSN1 critical interval and our YAC-based physical map. The order of markers within individual expressed-sequence-tag (EST) bins was determined, when possible, by use of information from published linkage maps (Genome Database), as well as by

Table 1
Haplotype Analysis of Families with HSN1

FAMILY	ALLELE AT MARKER ^a													MAXIMUM LOD SCORE	ORIGIN ^b	MUTATION	
	D9S1836	D9S1796	D9S255	D9S1815	D9S1841	D9S1781	71J15	20L24	20L24TA	D9S151	D9S12	D9S12II	D9S1803				D9S197
1	2	5	3	3	3	6	7	4	1	5	7	2	3	6	7.45	A/E	399T→G
2	2	5	3	3	3	6	7	4	1	7	3	4	2	5	1.18	A/E	399T→G
6	2	5	3	3	3	6	7	4	1	5	7	2	3	6	.76	A/E	399T→G
22	2	5	3	3	3	6	7	4	1	5	7	2	3	6	1.12	W	399T→G
23	2	5	3	3	3	6	7	4	1	5	7	2	3	6	4.30	W	399T→G
24	2	5	3	3	3	6	7	4	1	5	7	2	3	6	.98	W	399T→G
4	3	4	3	5	4	5	4	1	9	5	7	2	5	2	1.14	A/E	341T→A
16	3	4/5/7? ^c	3	3	1	5	4	1	9	8	7	2	3	5	.58	L	399T→G
20	1/2? ^c	1	3	3	5	1	7	4	3	5	3	4	1	2	1.79	Au	398G→A

^a For details of markers and assignment, see text. The common haplotype, in families 1, 2, 6, 22, 23, and 24, and a group of common alleles, in families 4 and 16, are indicated by the larger and smaller boxed regions, respectively. D9S1781 and 71J15 flank the region containing the *SPTLC1* gene.

^b A/E = Australian, of English extraction; W = Wiltshire, in southern England; L = London; Au = Austria.

^c Disease allele unknown, because marker was uninformative in the family.

use of sequence data and bacterial-artificial-chromosome (BAC) contig maps of the region that, as part of their project to sequence chromosome 9, were generated by the Sanger Centre.

For each of the 14 markers, alleles associated with HSN1 were identified in each family with HSN1, and a disease haplotype was constructed. Haplotypes spanning these markers were also determined in 50 controls (100 chromosomes), consisting of those married-in spouses and individuals of known English extraction for whom samples were available from three generations. Statistical analysis, to compare the frequency of disease-carrying haplotypes to that of controls, was performed by the χ^2 test, with 1 df and the Yates continuity correction for a 2×2 contingency table.

Only two families with HSN1 were large enough to show definite linkage (LOD score >3) to chromosome 9. Maximum LOD scores for each family are shown in table 1. Linkage to chromosome 9 was not excluded in any family. Most families were too small to yield a significant LOD score, but, in each of these small families, we were able to identify a disease haplotype that was shared by all affected family members. No recombination events within the HSN1 critical interval were observed in any individuals in these families.

Table 1 shows HSN1 chromosome haplotypes. An extended haplotype spanning the nine markers—D9S1836, D9S1796, D9S255, D9S1815, D9S1841, D9S1781, 71J15, 20L24, and 20L24TA—was present in 6 of the 9 disease chromosomes studied but in 0 of the 100 control chromosomes studied ($\chi^2 = 58.32$; $P < .0001$). These results provide strong evidence for a common founder for these families. A group of common alleles was found, with markers 71J15, 20L24, and 20L24TA, in 2 of the 9 disease chromosomes (in families 4 and 16), compared to 28 of the 100 control chromosomes, but this smaller haplotype was not statistically significant ($\chi^2 = 0.00$; $P = .986$). Families 4 and 16 exhibit different *SPTLC1* mutations, providing further evidence against a common founder for these two families.

Five of the six families with HSN1 who share the 9-marker haplotype, from D9S1836 to 20L24TA, have a larger haplotype—spanning 14 markers, from D9S1836 to D9S197 (table 1); family 2 shares the common 9-marker haplotype, to marker 20L24TA, but the haplotype diverges at the next marker, D9S151 (see table 1), indicating a historical recombination between D9S151 and the gene mutation.

In this study, we have identified, in the largest of the families that we studied (family 1), an HSN1 haplotype that is common to families 2, 6, 22, 23, and 24. Given the strong statistical evidence ($P < .0001$), it is highly unlikely that the common haplotype occurs by chance. No control families of English extraction had the same haplotype, indicating that the common haplotype was

present in $<1/50$ families. These results suggest a common founder for the three Australian and the three Wiltshire families with HSN1.

One of the Wiltshire families with the common haplotype had come from London and therefore may be related to the London/Exeter family studied by Hicks (1922), but no records for the London/Exeter family can be found. The clinical phenotype in the families with the common chromosome 9 haplotype is similar to that in the family studied by Hicks (1922), with frequent but not invariable deafness, severe shooting or lancinating pains in some affected individuals, and late-teenage- or adult-onset CMT type 2. This lancinating pain/deafness HSN1 phenotype was recognized by Dyck et al. (1993). Family 20, an Austrian family, has this phenotype as well as a different *SPTLC1* mutation with a different haplotype, suggesting a separate founder.

Shooting pains and deafness were not reported in either the families with chromosome 3 linkage (De Jonghe et al. 1997; Elliott et al. 1997) or the family in which loci of chromosomes 3 and 9 were excluded (Auer-Grumbach et al. 2000). These associated features may therefore help to distinguish between families with HSN1 and families with other forms of hereditary sensory neuropathy and CMT neuropathy.

The haplotype information suggests that a number of Australian and English families are descended from a common southern-English founder; this is supported by our finding the same phenotype and mutation (399T→G) in such families. Historical information shows that the founder lived in southern England prior to 1800, the date of deportation, from Wiltshire, of the convict ancestor of family 1 (Wallace 1969). The neuropathy phenotype caused by the 399T→G *SPTLC1* mutation is the same as that reported by Campbell and Hoffman (1964) and, possibly, the same as that originally described by Hicks (1922). It is interesting that the family with the historical recombination (family 2) migrated to Australia from Trowbridge, a town in Wiltshire, near where three of the English families with HSN1 live.

Acknowledgments

We wish to thank Prof. P. K. Thomas (Royal Free Hospital, London) and Dr. M. Campbell (Department of Neurology, Fenchay Hospital, Bristol), for providing access to families in their care. Dr. D. Ellison (Melksham) kindly assisted in the relocation of a family (family 24) originally described in his University of Edinburgh M.D. thesis. Ms. M. Williams (Southmead Hospital, Bristol) kindly assisted with blood collections and DNA preparations. Dr. N. Wood (Institute of Neurology, London) contributed DNA from the London family (family 16). This work was made possible by the willing assistance of many Australian and English family members. Mr. R. Thorburn (Australian Genealogical Education Center) found the links between family 1 and the convict from Wiltshire. Finan-

cial support was provided through grants from the National Health and Medical Research Council (Australia) and from the Muscular Dystrophy Association (U.S.A.).

Electronic-Database Information

Genome Database, The, <http://www.gdb.org/> (for genetic maps of chromosome 9 area)

Online Mendelian Inheritance in Man (OMIM), <http://www.ncbi.nlm.nih.gov/Omim/> (for HSN1 [MIM 162400])

Sanger Centre, The, <http://webace.sanger.ac.uk/cgi-bin/webace?db=acedb9> (for chromosome 9 BAC sequence)

References

- Auer-Grumbach M, Wagner K, Timmerman V, De Jonghe P, Hartung HP (2000) Ulcero-mutilating neuropathy in an Austrian kinship without linkage to hereditary motor and sensory neuropathy IIB and hereditary sensory neuropathy I loci. *Neurology* 54:45–52
- Bejaoui K, McKenna-Yasek D, Hosler BA, Burns-Deater E, Deater LM, O'Neill G, Haines JL, Brown RH Jr (1999) Confirmation of linkage of type 1 hereditary sensory neuropathy to human chromosome 9q22. *Neurology* 52:510–515
- Blair IP, Hulme D, Dawkins JL, Nicholson GA (1998) A YAC-based transcript map of human chromosome 9q22.1-q22.3 encompassing the loci for hereditary sensory neuropathy type I and multiple self-healing squamous epithelioma. *Genomics* 51:277–281
- Campbell AMG, Hoffman HL (1964) Sensory radicular neuropathy associated with muscle wasting in two cases. *Brain* 87:67–74
- Dawkins JL, Hulme DJ, Brahmabhatt SB, Auer-Grumbach M, Nicholson GA (2001) Mutations in *SPTLC1*, encoding serine palmitoyltransferase, long chain base subunit-1, cause hereditary sensory neuropathy type I. *Nat Genet* 27:309–312
- De Jonghe P, Timmerman V, FitzPatrick D, Spoelers P, Martin JJ, Van Broeckhoven C (1997) Mutilating neuropathic ulcerations in a chromosome 3q13-q22 linked Charcot-Marie-Tooth disease type 2B family. *J Neurol Neurosurg Psychiatry* 62:570–573
- Denny-Brown D (1951) Hereditary sensory radicular neuropathy. *J Neurol Neurosurg Psychiatry* 14:237–252
- Dyck PJ, Chance P, Lebo R, Carney JA (1993) Neuronal atrophy and degeneration predominantly affecting peripheral sensory and autonomic neurones. In: Dyck PJ, Thomas PK (eds) *Peripheral neuropathy*. Vol 2. WB Saunders, Philadelphia, pp 1094–1136
- Elliott JL, Kwon JM, Goodfellow PJ, Yee WC (1997) Hereditary motor and sensory neuropathy IIB: clinical and electrodiagnostic characteristics. *Neurology* 48:23–28
- England AC, Denny-Brown D (1952) Severe sensory changes, and trophic disorder, in peroneal muscular atrophy (Charcot-Marie-Tooth type). *Arch Neurol Psychiatry* 67:1–22
- Hicks EP (1922) Hereditary perforating ulcer of the foot. *Lancet* 1:319–321
- Jackson M (1949) Familial lumbosacral syringomyelia and the significance of developmental errors of the spinal cord and column. *Med J Aust.* 1:434–439
- Kwon JM, Elliott JL, Yee WC, Ivanovich J, Scavarda NJ, Moolsintong PJ, Goodfellow PJ (1995) Assignment of a second Charcot-Marie-Tooth type II locus to chromosome 3q. *Am J Hum Genet* 57:853–858
- Nicholson GA, Dawkins JL, Blair IP, Kennerson ML, Gordon MJ, Cherryson AK, Nash J, Bananis T (1996) The gene for hereditary sensory neuropathy type I (HSN-I) maps to chromosome 9q22.1-q22.3. *Nat Genet* 13:101–104
- Thomas PK (1993) Hereditary sensory neuropathies. *Brain Pathol* 3:157–163
- Vance JM, Speer MC, Stajich JM, West S, Wolpert C, Gaskell P, Lennon F, Tim RM, Rozear M, Othmane KB, Pericak-Vance MA (1996) Misclassification and linkage of hereditary sensory and autonomic neuropathy type 1 as Charcot-Marie-Tooth disease, type 2B. *Am J Hum Genet* 59:258–262
- Wallace DC (1969) A study of an hereditary neuropathy. University of Sydney, Sydney
- (1970) Hereditary sensory radicular neuropathy. *Archdall Medical Monograph* 8. Australasian Medical, Sydney